



College of Optometry  
UNIVERSITY OF HOUSTON



# *Monthly InSight*

*Live Webinar Series*  
*2025*

# March Lecture Handouts

## Interpreting Gonioscopy

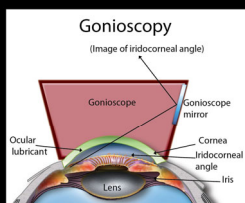
Marcus Gonzales, OD, FAAO

## Financial Disclosures

- No financial disclosures
- Marcus Gonzales OD, FAAO
- Clinical Associate Professor at the University of Houston College of Optometry
- Clinic Director of the Cedar Springs Eye Clinic
- 4<sup>th</sup> Year Rotation Site and Ocular Disease Residency

## Gonioscopy

- Evaluates the anterior chamber angle responsible for the outflow of aqueous



## Indications for Gonioscopy

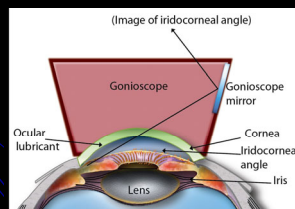
- Narrow angles
- Asymmetric IOPs
- Secondary open angle glaucomas
- Complications from retinal conditions
- Iris anomalies
- Trauma

## Contraindications/Cautions

- Corneal surface conditions
- Recent trauma
  - Hyphema
  - Globe perforation/laceration
- Chronic acute inflammatory conditions

## Types of Gonioscopy

- Direct vs Indirect



## Generalizations

- Superior angle is narrowest
- Inferior angle is the deepest
- WGA statement: Van Herick very predictive of angle depth

## Technique

- Remember why you're doing this
  - Don't use too much light
  - Don't use too large of a beam height
  - Don't use too much magnification
  - Don't panic!!
- Systematic approach

## Grading Systems

- Shaffer
- Scheie
- Spaeth

Iris Insertion	Angular Approach	Peripheral Iris	Pigmentation of Trabecular Meshwork
A. Anterior to Schwalbe's line	2° to 50°	r regular	0 no pigment
B. Between Schwalbe's line and scleral spur		b bowed anteriorly	1+ minimal
C. Scleral spur visible		p plateau iris	2+ mild
D. Deep with ciliary body visible		c concave	3+ moderate
E. Extremely deep with 1/3 area of ciliary body visible		q steep	4+ intense

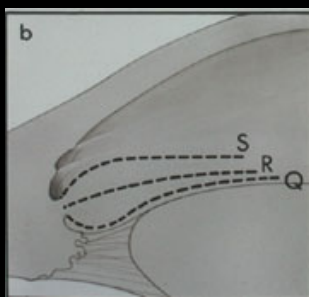
Marsh, Barbara C and Louis B. Cantor. "The Spaeth Gonioscopic Grading System Assessing the configuration of the anterior chamber angle."

## Keep It Simple!

- Document what you see in every quadrant
  - Contour of the iris
  - Deepest structure
  - Trabecular meshwork pigmentation
  - Angle characteristics (PAS, NVA, etc)

## Contour of the Iris

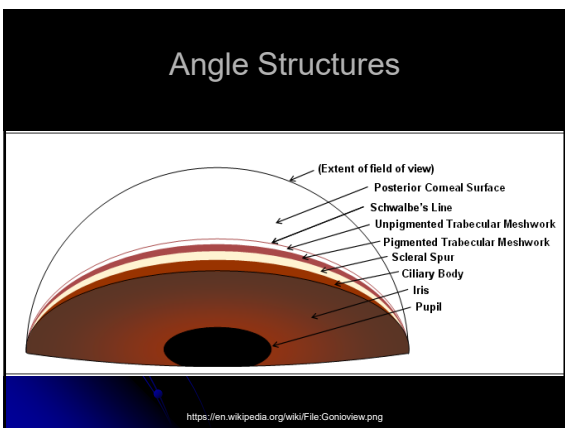
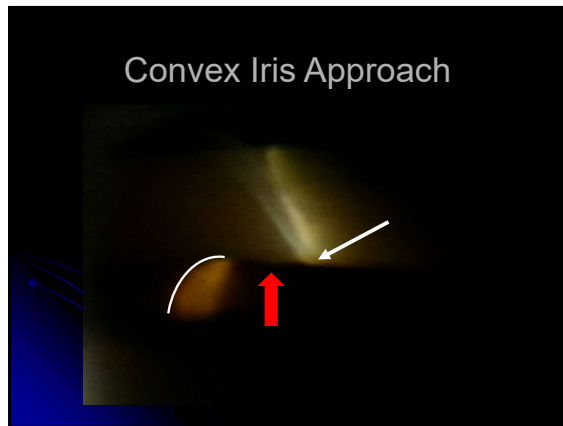
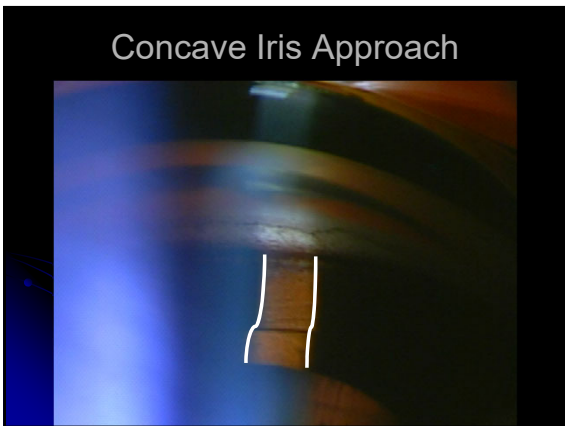
- Concave - Q
- Convex - S
- Flat - R



Foa AM, Bertina L, Consolani G, Damato D, Lorenzi U, et al. (2012) Angle Closure Glaucoma: Pathogenesis and Evaluation. A Review. J Clin Exp Ophthalmol 54:105.


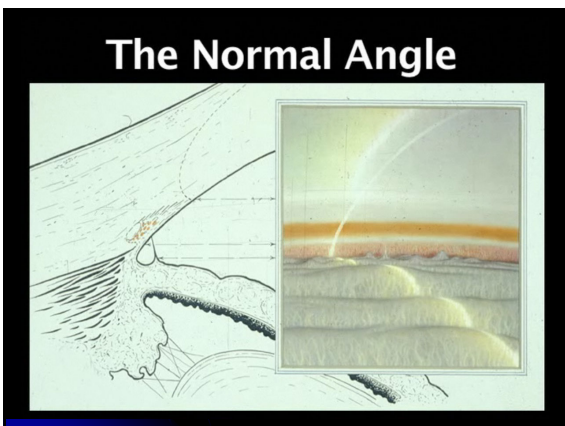
## Flat Iris Approach


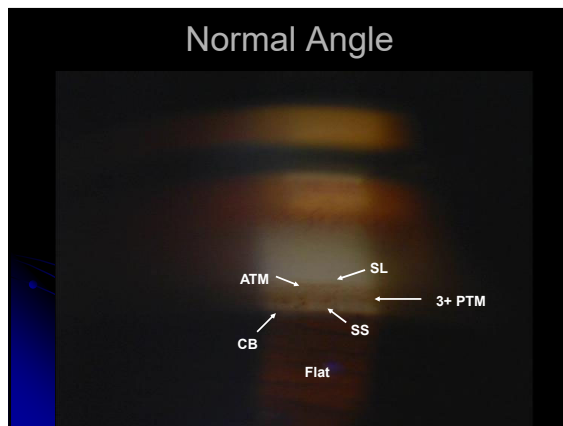
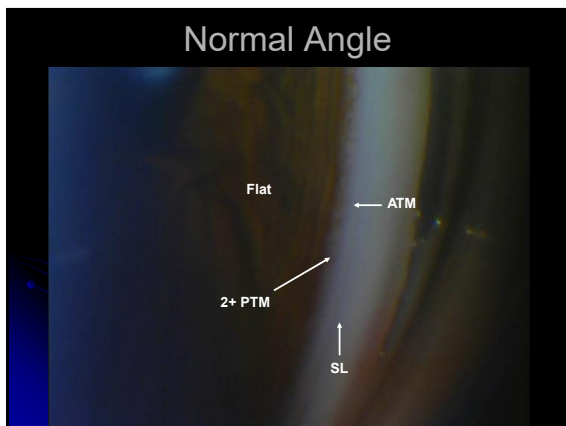




### Trabecular Meshwork Pigmentation

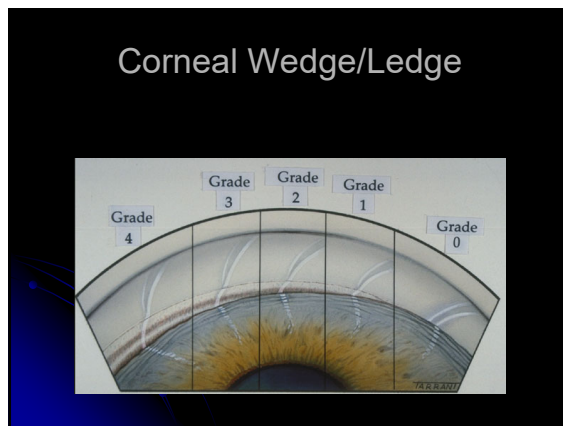
Grade:	Pigmentation:
• 0	no pigmentation
• Trace	very little pigmentation
• 1+	mild pigmentation
• 2 - 3+	moderate pigmentation
• 4+	marked pigmentation

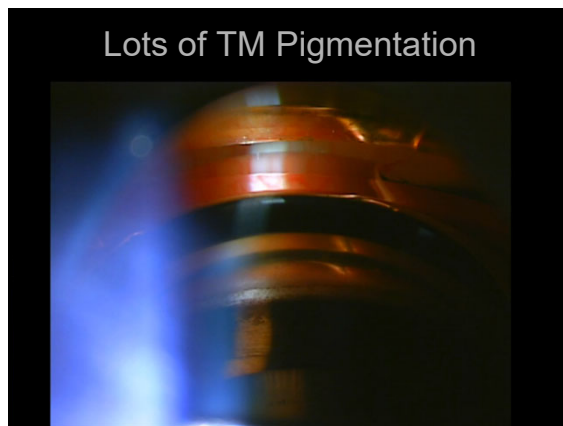
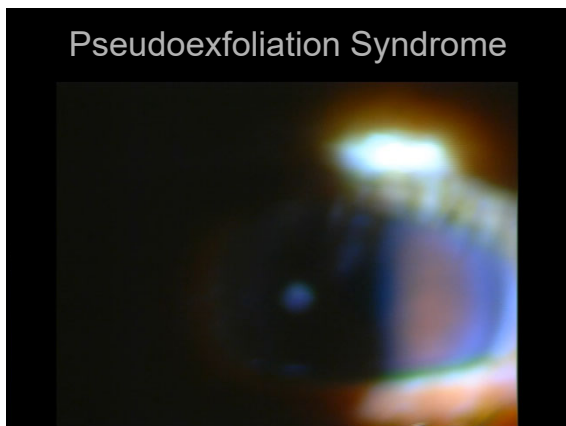
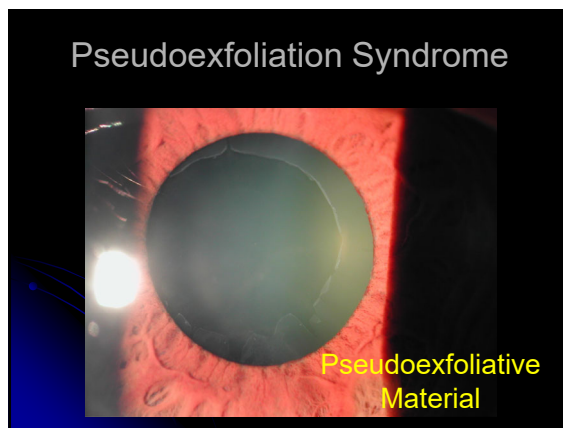
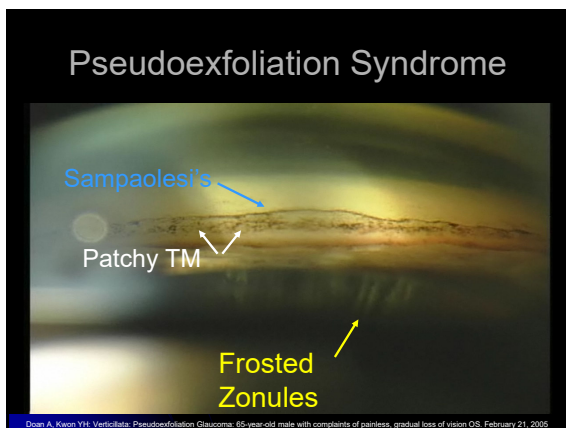
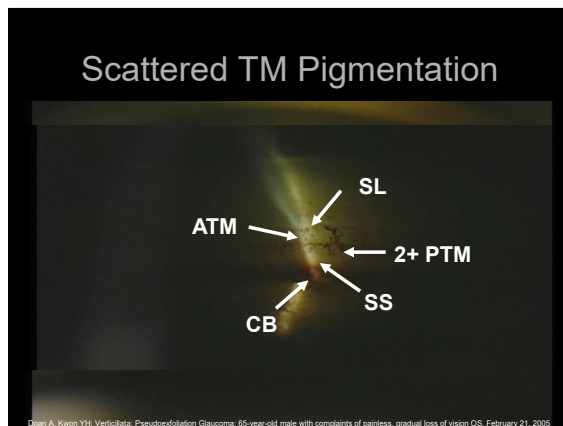




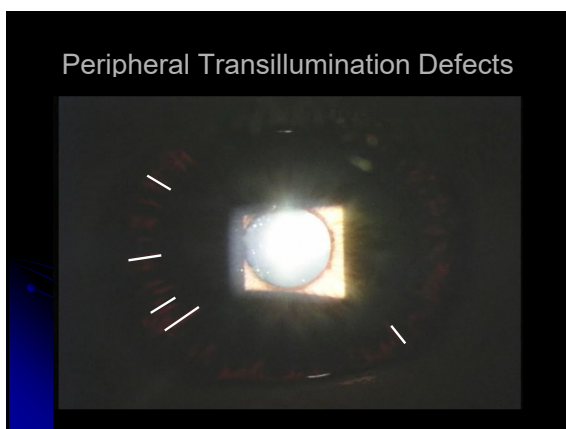

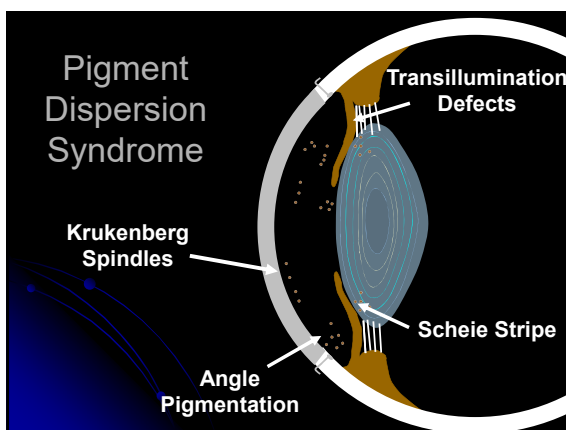
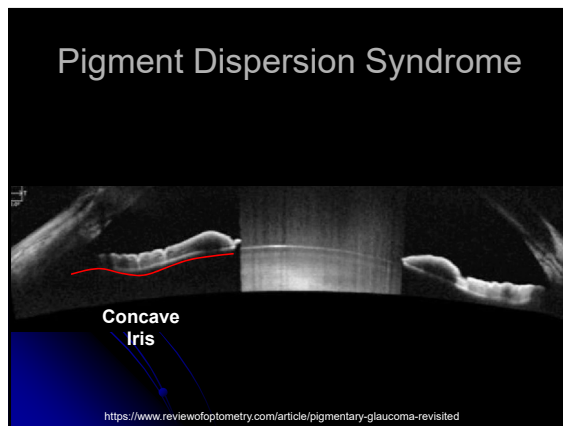
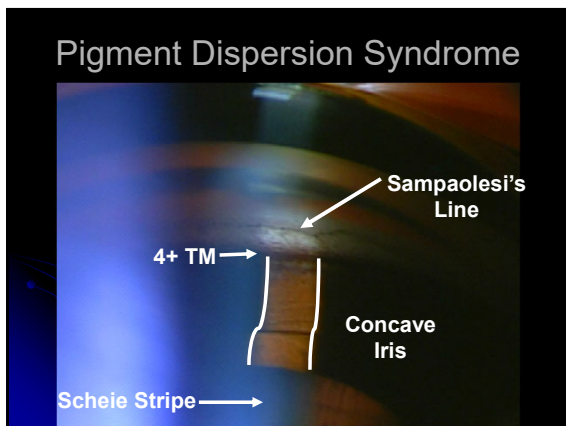


- ### Corneal Wedge/Ledge
- Determines location of Schwalbe's line
    - Narrow angles or irregular TM pigmentation
  - Can be done with any gonio lens
    - Easier with flange gonio lens
  - Focus more on corneal aspect of angle
    - May have to tip the lens

- ### SLE Settings
- Housing unit: 20-30° off-axis
  - Beam type: optic section
  - Beam orientation: perpendicular to angle
  - Illumination: bright
  - Magnification: medium to high (16-24x)

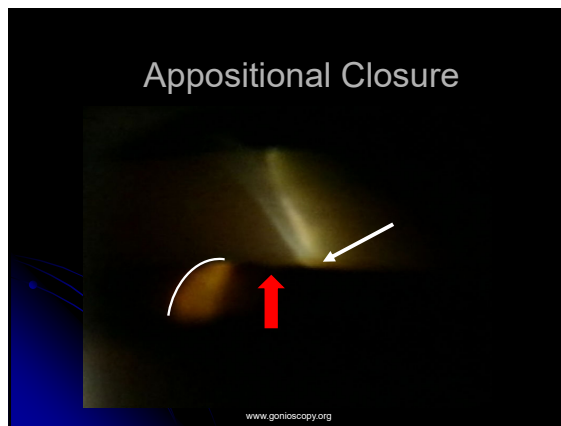
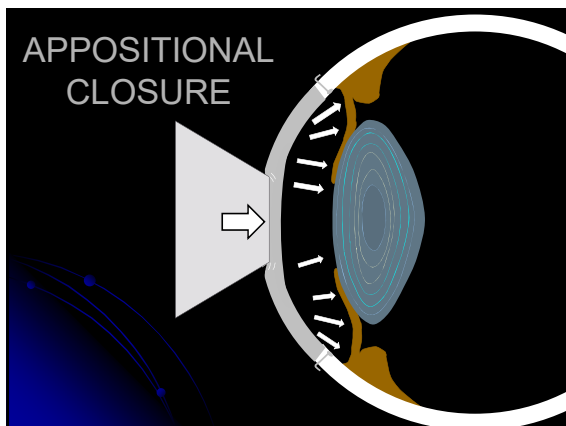

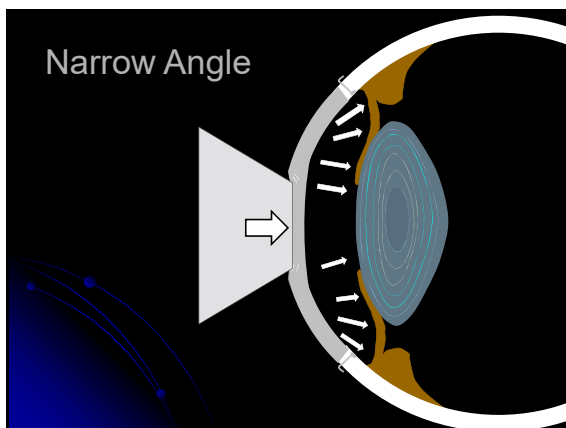
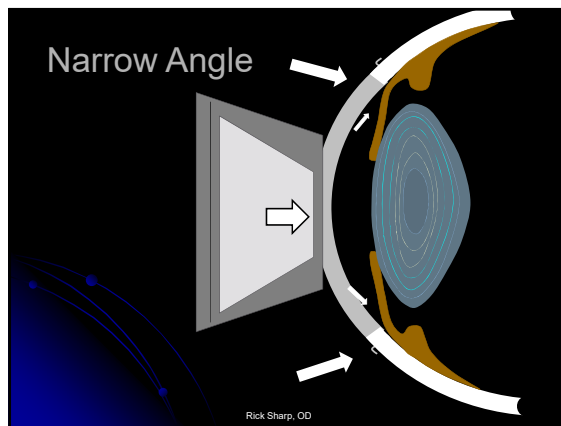


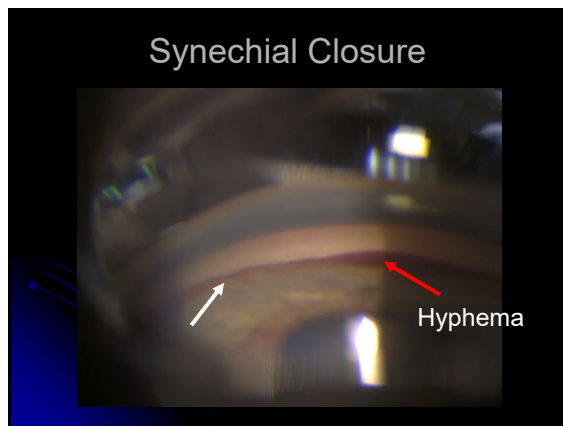
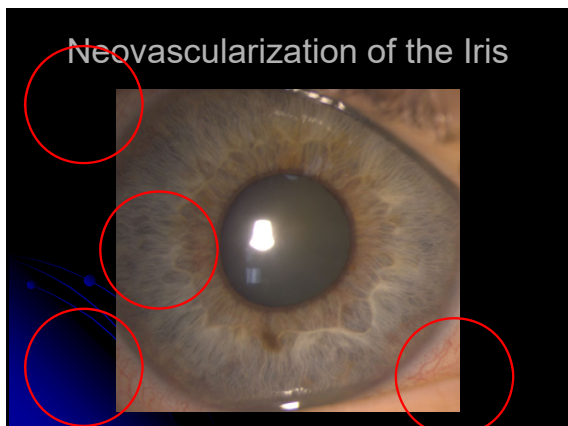
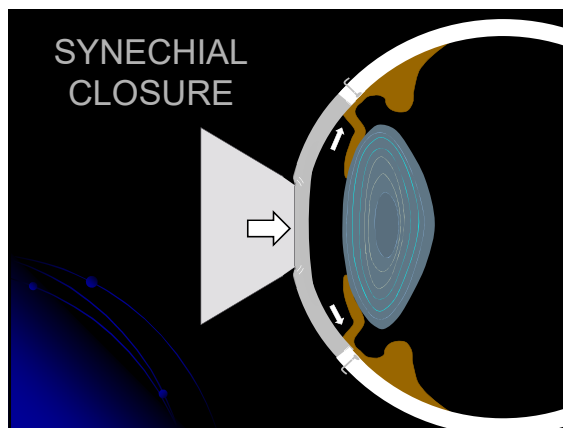
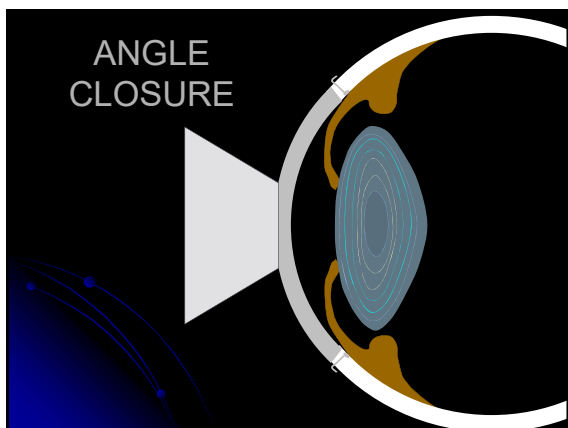






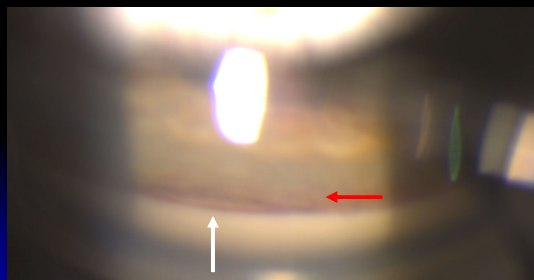
### Compression

- Evaluates iris movement
- Need non-flange gonio lens
- Gently push in a pulsatile manner
- Peripheral iris bows backward giving a deeper angle (extent depends on iris contour)
  - Angle opens in appositional closure
  - Angle will not open in synechial closure
- Pupil can elevate giving a volcano-look

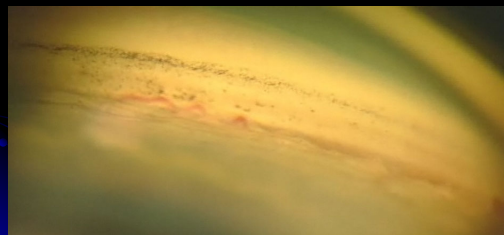




### Synechial Closure



### Normal Blood Vessel



### Normal Blood Vessel




### Angle Characteristics

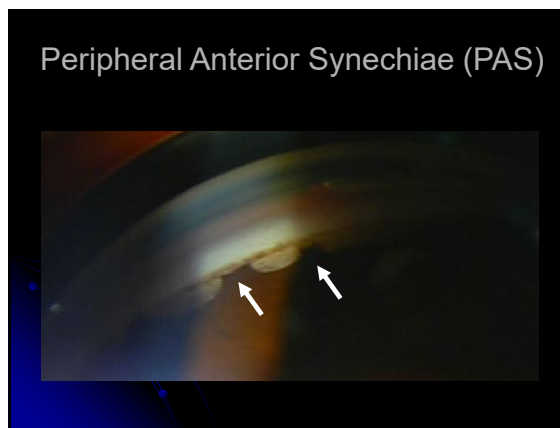
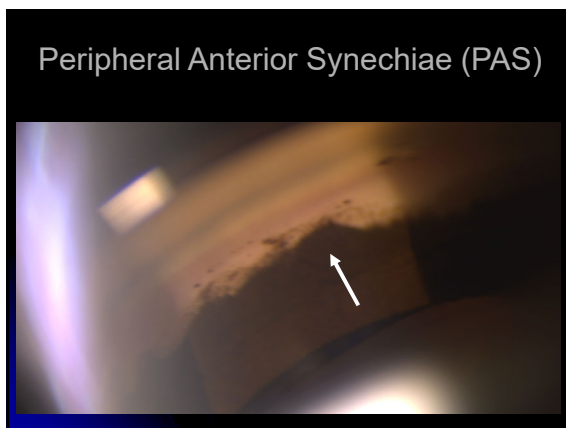
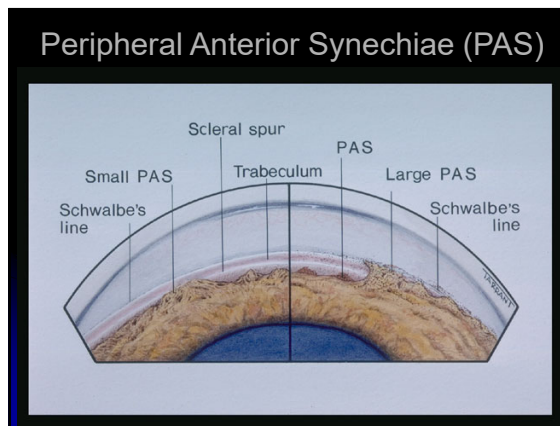

- Iris processes
- Peripheral Anterior Synechiae (PAS)
- Angle Recession

### Iris Process vs PAS

- Iris Process
  - Thin, small string
  - Usually attaches to the SS and TM
  - Pushes back with compression
- PAS
  - Thick, broad band
  - Usually attaches to the TM and cornea
  - Doesn't push back with compression

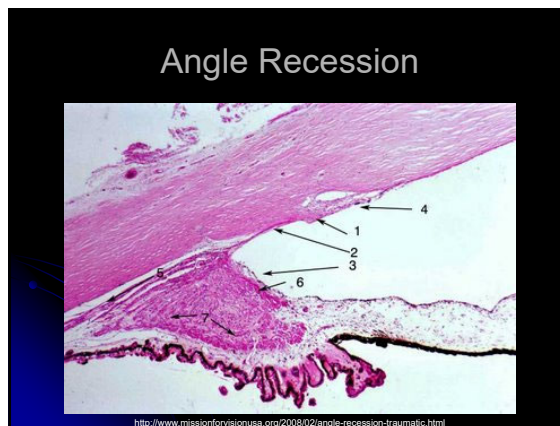
### Iris Process

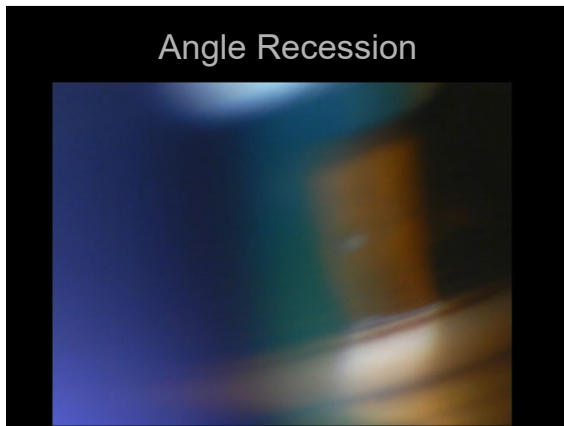




### Angle Recession

- Blunt trauma that results in a tear in the longitudinal and circular muscles in the ciliary body
- Symmetrical amount of CB btwn eyes
- High association with hyphemia
- Strong risk factor for glaucoma for the rest of the patient's life





### Pearls

- Use a systematic approach
- Utilize corneal wedge/ledge technique
- Utilize compression technique
- Practice on normals
- Go learn at....

[www.gonioscopy.org](http://www.gonioscopy.org)

### Thank you for your attention

Questions?

[mbgonzal@central.uh.edu](mailto:mbgonzal@central.uh.edu)